

Addressing Needs, **Surpassing** **Expectations.**

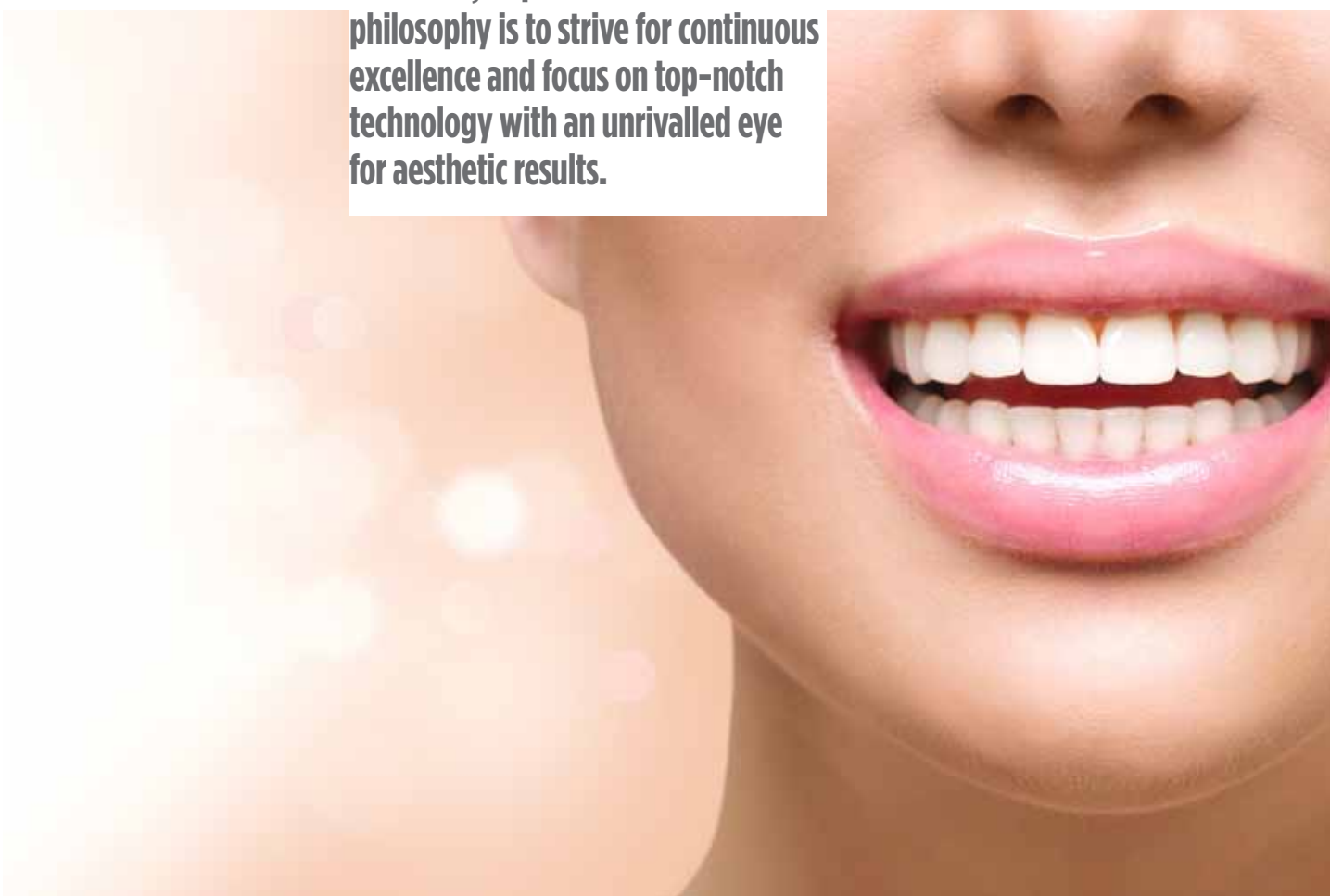
The Imperial Dental Specialist Centre advantage.

Treating hundreds of patients on a weekly basis, the Imperial Dental Specialist Centre is not only accredited by Global Clinic Rating (GCR) but also recommended as one of the premier dental facilities in Malaysia. Winning multiple awards and accolades, Imperial Dental's philosophy is to strive for continuous excellence and focus on top-notch technology with an unrivalled eye for aesthetic results.

Winning multiple awards and accolades, Imperial Dental's philosophy is to strive for continuous excellence and focus on top-notch technology with an unrivalled eye for aesthetic results.

Providing a plethora of oral treatment from orthodontics and dental prosthetics to holistic oral care, the Imperial Dental Specialist Centre truly is your one-stop-centre for all your dental treatment needs.

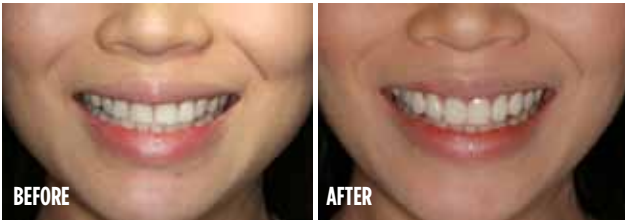We speak to three of Imperial Dental's doctors as they explain a few of the many procedures available at this modern centre and reveal how such treatments and technologies not only improve form but also function, for a better quality of life.



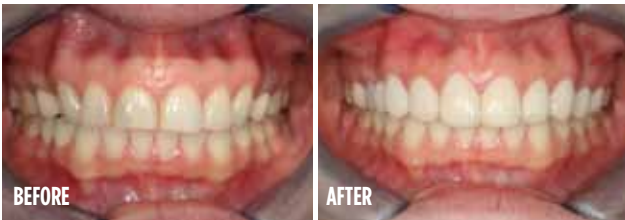

Designing smiles via 3D Digital Smile Technology with Consultant Orthodontist, Dato' Dr. How Kim Chuan

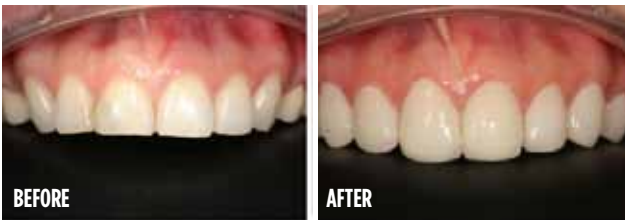Pictures courtesy of Dato' Dr. How Kim Chuan.



Full face smile achieved. The shape, size and shade of the teeth were customised to the patient's facial profile, creating an attractive smile aesthetic.



The gingival level was lengthened using laser gingivoplasty. It's a painless, bloodless procedure which affects in zero downtime.



The size and shape of the teeth were created based on Golden Proportions.

At the Imperial Dental Specialist Centre, we are capable of designing unique, natural and proportional smiles with 3D Printing Technology, without any added use of metallic crowns. Before clients and patients are given new, permanent crowns, provisional prosthetics are placed in the patients' mouth in order to design and customise the perfect smile that befits each and every unique facial shape and characteristic.

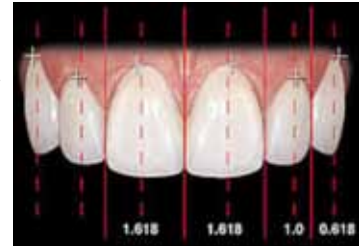
Once a patient is pleased with initial customisations, we will take impressions and design the perfect smile using our computer software. As soon as patients are satisfied with both provisional prosthetics and 3D designs, both doctor and patient will decide on perfect shades and sizes of the crowns.

When it comes to tooth sizes, the Imperial Dental Specialist Centre always customises dental prosthetics based on Golden Proportions. The law of Golden Proportion is a mathematically constant ratio between larger and smaller lengths, and has consistently been offered as the corner stone of smile design theory. By incorporating this law, patients will always leave our centre with tooth sizes that aren't only precise, but in pleasing proportions as well.

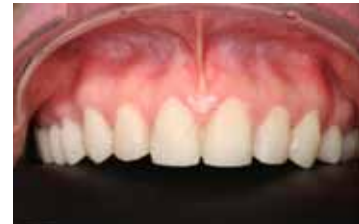Following the perfect customisation of a patient's crowns, we will fabricate permanent crowns singularly based on the

The law of Golden Proportion is a mathematically constant ratio between larger and smaller lengths, and has consistently been offered as the corner stone of smile design theory.

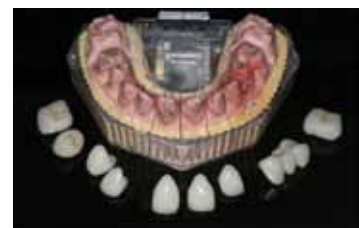The Golden Proportion is a mathematically constant ratio between the larger and smaller length. The ratio is approximately 1.618:1. In terms of measurements, the smaller tooth is about 62% the size of the larger one. The concept of Golden Proportion have often been offered as the corner stone of smile design theory.



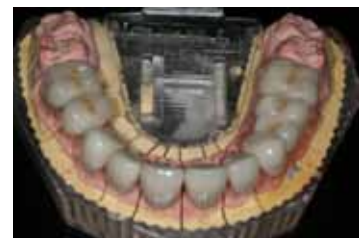Provisional veneers were customised based on a patient's taste and desired aesthetic.



EMAX crowns fabricated using 3D digital printing technology.



EMAX crowns aren't only metal-free but also present with tooth refractivity that are close to natural tooth enamel.

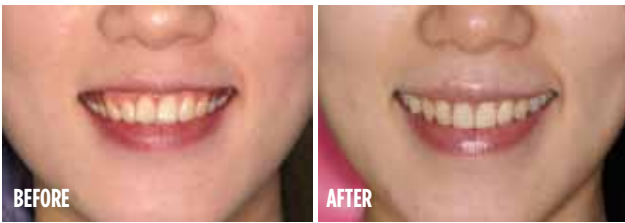


collected data. After unique prosthetics are ready, crowns will be fitted in, providing patients with perfect full-face smiles sans dark corner pockets even during smiling. Last but certainly not least, we additionally offer laser gingivoplasty. With this procedure, lasers are utilised to reshape the gum line, creating improved gingival shapes, plus teeth that look longer and slimmer, providing ideal aesthetic results.

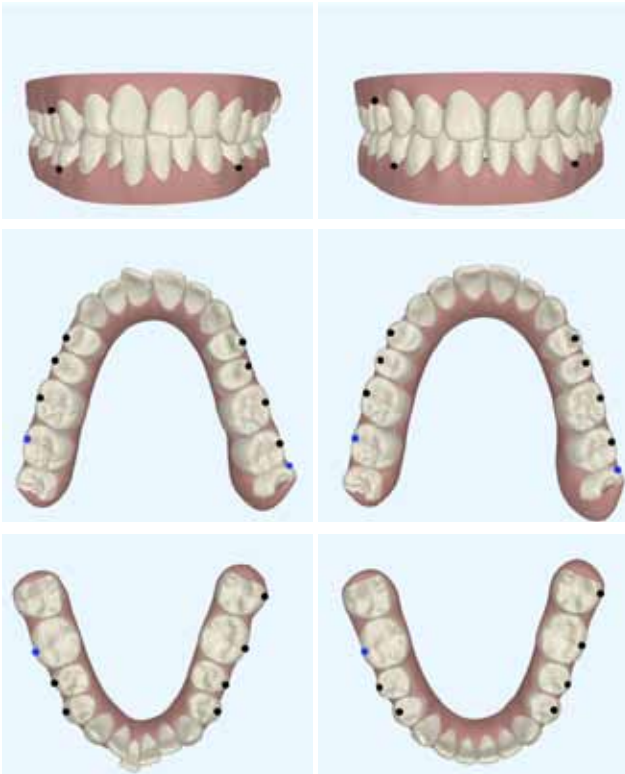

Digital Smile Design through Invisalign with Consultant Orthodontist, Dato' Dr. How Kim Chuan

Pictures courtesy of Dato' Dr. How Kim Chuan.



Gummy smile with canting of the occlusal plane corrected with Invisalign, creating a beautiful smile arc.

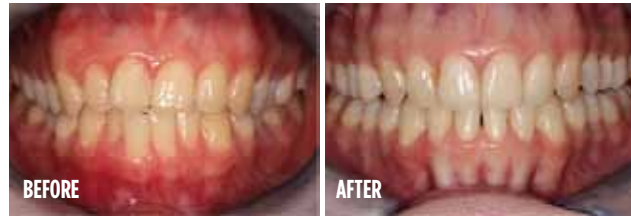

Clincheck planning predictions coincided with actual achieved results.

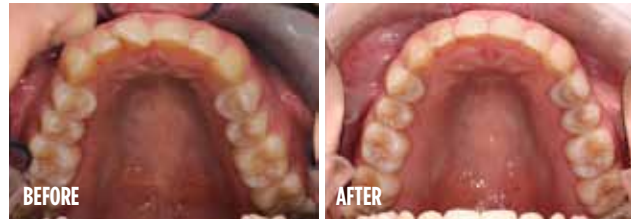Based on the photos, one can see that this patient not only sports a gummy smile, but a canting or slanting of the occlusal plane as well. Likewise, she also presented with Class 3 (underbite) edge to edge malocclusion with crowding. Through invisible Invisalign treatment we were able to correct this patient from a Class 3 malocclusion to a Class 1 through positive overjet and overbite.

Next, we similarly resolved crowding in the upper arch and concurrently brought symmetry to both the teeth and smile. Based on this patient's ClinCheck movement prediction, or digital before and after forecast, we were very closely able to achieve the best possible result or clinical outcome.

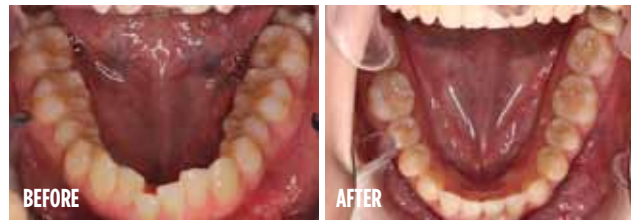With images in hand, it was clear that with Invisalign, this



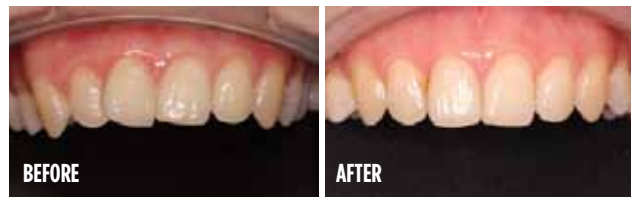Patient presented with Class 3 edge to edge malocclusion with crowding. The malocclusion was corrected to optimal Class 1 via positive overjet and overbite.



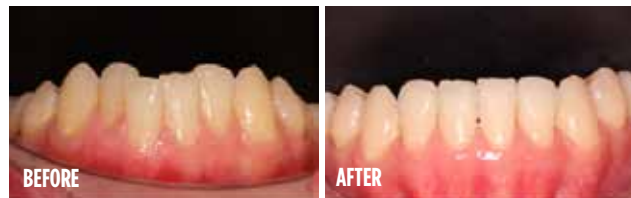The archform has been corrected to a symmetrical parabolic shape.



Lower crowding corrected, allowing for easier oral hygiene and maintenance.



Canting of the occlusal plane was levelled, creating a beautiful smile arc.



Overeruption of the lower teeth levelled, resulting in an optimal curve of Spee.

Invisalign's Digital Orthodontic Alignment System is the future of modern orthodontics where it's not only inconspicuous and less painful, but also rapidly replacing the conventional bracket system.

patient was able to accomplish a finished archform that's not only aligned, but also positioned in an optimally aesthetic manner. In summation, Invisalign's Digital Orthodontic Alignment System is the future of modern orthodontics where it's not only inconspicuous and less painful, but also rapidly replacing the conventional bracket system.



Normal Vs. Abnormal Appearances of the Gums and Teeth with Consultant Dentist, Datin Dr. Alice Wong

Dental Abscesses

Dental abscesses are a localised collection of pus associated with a tooth. The origin of such abnormalities is bacterial infection which has accumulated in the soft – often dead – pulp of the tooth. This can be due to various combination factors including tooth decay, broken teeth, extensive periodontal disease and failed root canal procedures. Treatment of dental abscesses is a reduction or elimination of offending organisms through antibiotics or drainage. If the affected tooth can be restored, root canal therapy may be recommended. Non-restorable teeth however, must be extracted followed by a curettage of all apical soft tissue.

Itchy Gums and Swollen Gums

Itchy gums can stem from a range of causes like allergic reactions after extraction, or eating, or bacterial infections that have built up between gums and teeth. Treatment can be resolved with simple home remedies comprising of gargling with salt water or antibacterial mouthwash, and sticking to good oral and dental hygiene practices.

Swelling throughout the body is never normal. If patients have swollen gums, this is normally accompanied with bleeding, pain and bad breath. Common causes of swollen gums are plaque and tartar, food residue, allergic reactions, old and faulty tooth restoration, misaligned teeth, medications, hormones and abscesses. For best treatment recommendations, visit your dentist as soon as possible.

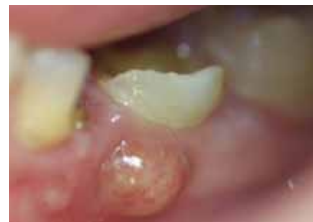Oral Mucocele

This abnormality (commonly a bluish translucent colour) is swelling of the connective tissue due to collection of mucus. It occurs because of a ruptured salivary gland, and is normally caused by local trauma. Commonly found in children or young adults, some mucoceles may spontaneously resolve on their own while others may turn chronic and require surgical removal. Recurrence may occur so preventative measures call for further excisions of adjacent salivary glands.

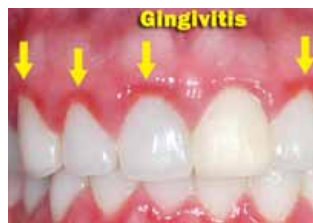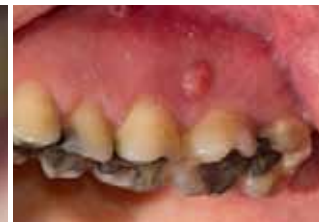Black, Brown and White Spots on Teeth

Black spots are caused by the erosion of the teeth's enamel. These spots can be as tiny as pen marks, or big enough to cover a lot of the tooth's surface. Treatments include at-home or in-office whitening systems.

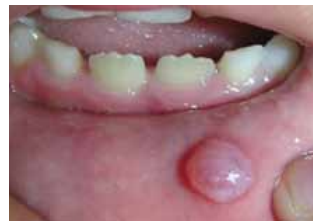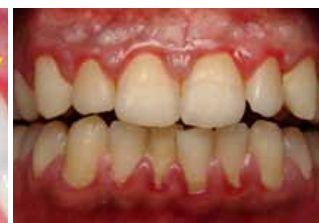Commonly found in children or young adults, some mucoceles may spontaneously resolve on their own while others may turn chronic and require surgical removal.



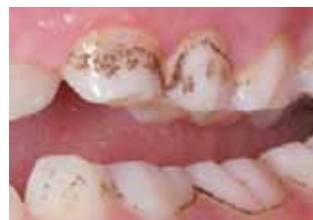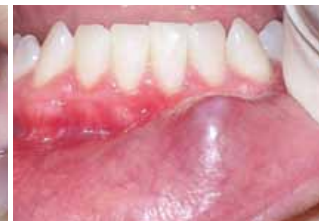Dental abscesses.



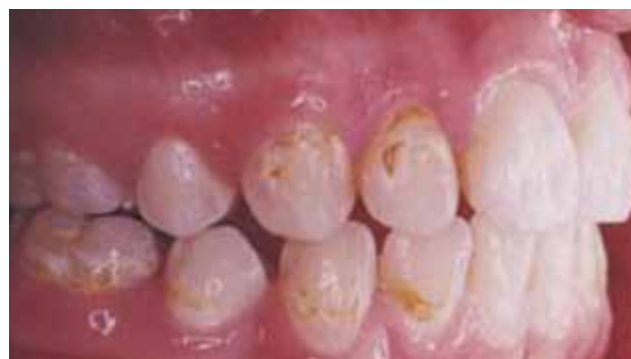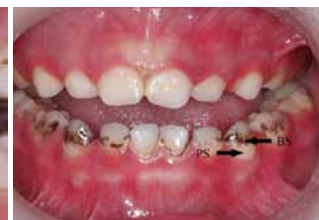Inflammation of gum tissue or gingivitis.



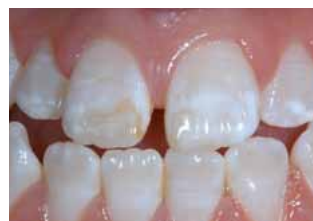Oral mucocele.



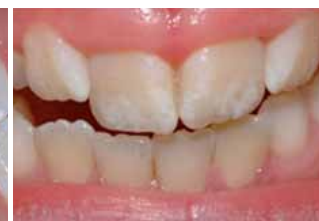Black spots on teeth.



Brown spots on teeth.



White spots on teeth.



Brown spots are due to internal and external factors like decay, tartar, fluorosis and Celiac Disease. If brown spots are confirmed to be extrinsic stains, clinical treatments in the form of restoration, polishing or whitening should do the trick.

White spots are the result of numerous influences, beginning with fluorosis. This condition damages the tooth's enamel because of excessive fluoride intake when a child's teeth are developing. Treatment may entail improved oral hygiene, CCP-ACP gum, CPP-ACP paste, microabrasion, resin filtration, composite bonding and porcelain veneers.

Pictures courtesy of Datin Dr. How Kim Chuan.



**Smile Makeover with
Dr. Raymond Su Wei
Siong DDS (UKM), Msc
Dental Implantology
(UCLan, England), FICD**

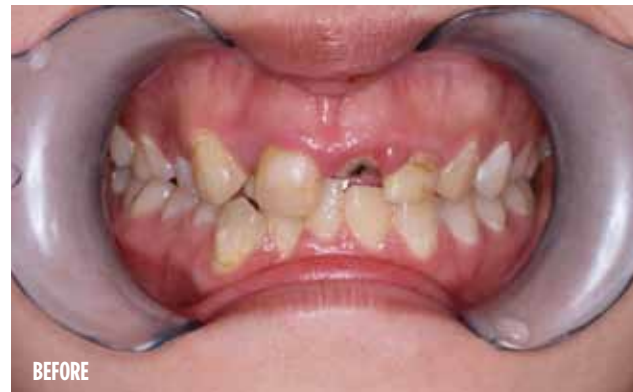When patients have a desire for aesthetically-pleasing smiles, they'll typically require multidisciplinary approaches, as single procedures cannot fix numerous problems. In short, patients may need combination procedures like crowns, root canals and dental alignment for optimal outcomes. Take for example the pictures included. This patient presented not only with a fractured, missing front tooth, her teeth were also terribly short, crowded and discoloured. Because this patient was unhappy with her looks, I came up with a treatment plan in order to create the best smile for her facial features.

When patients have a desire for aesthetically-pleasing smiles, they'll typically require multidisciplinary approaches, as single procedures cannot fix numerous problems.

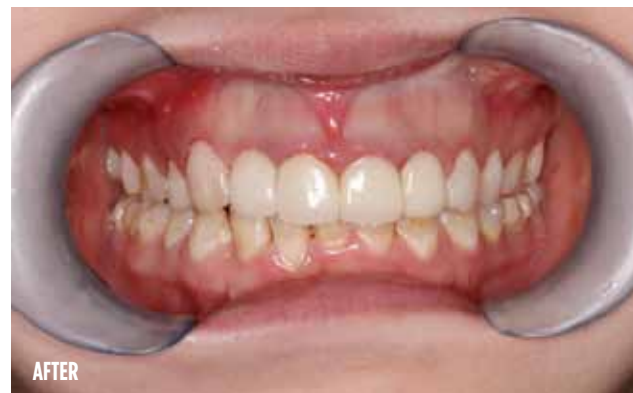Before procedures were carried out, I first took an impression of her teeth, casting it into a study model. We then took photographs of her original mouth and later, sat down with the patient to discuss needs and expectations.

When creating ideal smiles, we need to take into account unique facial profiles, as one size never fits all. Next, we also have to bear in mind the tooth's shape, as we have to coordinate shapes with facial characteristics. For example, if patients have large faces, small teeth won't look balanced or harmonious. Last but not least, both doctor and patient must decide the tooth's colour and positions so that expectations are met.

Based on the photos attached, although this patient underwent initial crowning and root canal treatment, crowding still posed problems, as dental alignment wasn't established. Hence, I recommended orthodontic treatment with Invisalign. Once we got teeth in to optimal positions, we moved on with more crown procedures including added touch-ups to achieve prime proportions. Finally, and after multiple combination procedures including Invisalign, crowns and root canal treatment, this patient was able to walk out of our centre with a better smile and a new lease on life.



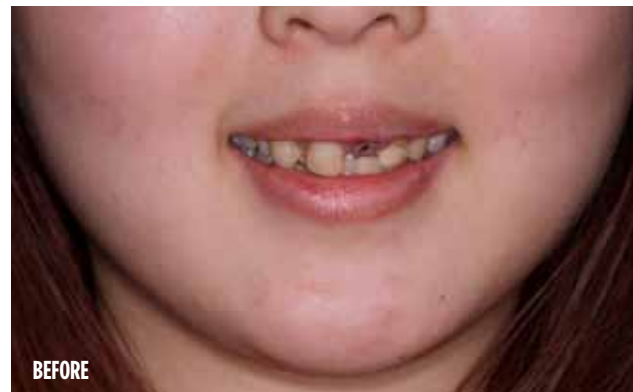BEFORE



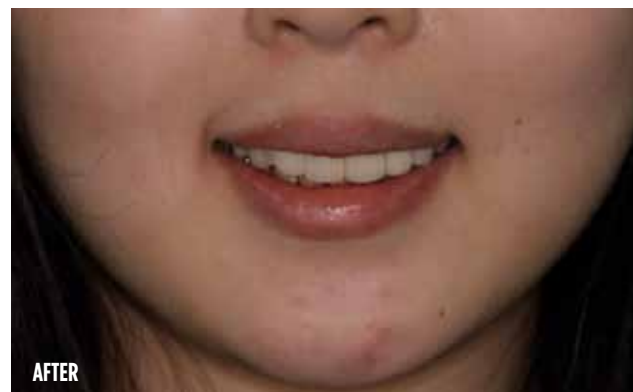AFTER

This patient was recommended a smile makeover program via a multidisciplinary approach.

She underwent root canal treatment for a reconstruction of badly broken down teeth. In addition, she also chose orthodontic treatment with Invisalign to correct the crowding and malocclusion. Last but not least, crowns were also fitted in her mouth, creating a beautiful smile arc.



BEFORE



AFTER

Pictures courtesy of Dr. Raymond Su Wei Siong.